

342 Minimizing Intraoperative Hemorrhage in Wound Debridement using a Novel Topical Hemostatic Agent

T. Xu, MD, K. Kramer, MD, E. Koeck, MD,

F. Bokhari, MD, S. Poulakidas, MD

Rush University Medical Center, Chicago, IL; John H. Stroger Jr. Hospital of Cook County, Chicago, IL

Introduction: Hemorrhage control presents unique challenges in burn surgery. Given the tenet of early excision for source control, the ability to limit hemorrhage is critical as excess blood loss can preclude the timely removal of burns and grafting. Traditional techniques of suture ligation and electrocautery are time-consuming with major blood loss still occurring. Burn excision also produces “non-compressible” hemorrhage not amenable to traditional techniques. Topical hemostatic agents have been developed to mitigate these issues. One novel agent uses an etherified sodium carboxymethyl cellulose to make a water-soluble, bioresorbable nanocellulose matrix. We present a series of ten patients where hemorrhage was mitigated with this product.

Methods: Ten patients were enrolled who were admitted to a single verified burn center for burn management between July and September 2018. All patients underwent tangential excision and debridement of their deep partial- or full-thickness burns, with immediate post-debridement application of the study topical hemostatic agent. This was left in place for twenty minutes prior to checking hemostasis and securing the split-thickness skin graft.

Results: By previous protocol, hemostasis would be achieved with an epinephrine-soaked collagen and silica based compression dressing followed by suture ligation and electrocautery to control any remaining hemorrhage. In our series, the study agent was placed over the wound bed immediately after debridement, followed by a dry collagen and silica based dressing wrapped in a compressive fashion and left in place for twenty minutes. It was then taken down and hemostasis achieved. In our series, excised areas were 90% hemostatic with small punctate hemorrhages easily controlled with electrocautery; suture ligation was rarely needed. Conventional methods achieved approximately 30% hemostasis; the remainder required a combination of suture ligation and electrocautery for complete hemostasis.

Conclusions: Topical hemostatic agents are useful adjuncts for hemorrhage control. Our case series presents a treatment option in patients undergoing extensive burn debridement with high intraoperative blood loss. We anticipate broader applications for hemorrhage control, thus limiting blood loss and transfusion requirement.

Applicability of Research to Practice: In this case series, etherified sodium carboxymethyl cellulose provided inexpensive, timely, and adequate hemostasis in an operative field where complete hemostasis is essential for skin grafting. This leads to decreased operative times and decreased overall blood loss. Further studies are needed to elucidate other benefits.

S148

American Burn Association 51st Annual Meeting

Journal of Burn Care & Research, Volume 40, Issue Supplement_1, April 2019, Page S148,

<https://doi.org/10.1093/jbcr/irz013.253>

Published: 08 March 2019

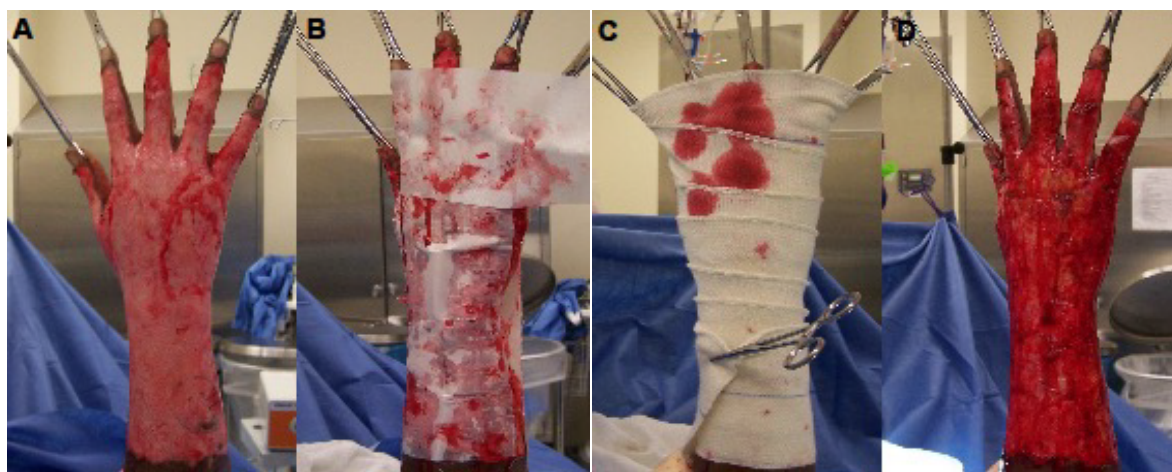


Figure 1: (A) Intraoperative pre debridement, (B) Application of hemostatic agent, (C) Wrapping of compression dressing, (D) Dressing takedown